

# Anterior segment-optical coherence tomography for evaluation of the epithelium thickness profile in keratoconic corneas and normal corneas

Soha M.M. Eltohamy

Department of Ophthalmology, Benha Faculty of Medicine, Benha University, Benha, Egypt

Correspondence to Soha M.M. Eltohamy, MD, Department of Ophthalmology, Benha Faculty of Medicine, Benha University, Street No. 3, Villa 12 Kornish Elneel, Benha, Qalubia 11511, Egypt. Tel: +20 122 067 6798; e-mail: sohamoussa21@gmail.com

**Received:** 17 July 2021

**Revised:** 24 September 2021

**Accepted:** 27 September 2021

**Published:** 21 December 2021

**Journal of the Egyptian Ophthalmological Society** 2021, 114:110–115

## Purpose

This study intends to compare the characteristic distributive epithelial pattern by Fourier-domain anterior segment-optical coherence tomography (AS-OCT) corneal mapping between keratoconic and normal eyes.

## Patients and methods

This prospective case–control study included 51 participants who were divided into two groups: study group A (formed of 50 eyes of 26 keratoconic participants) and control group B (50 eyes of 25 healthy controls of matched age and sex with group A). Maps of corneal epithelial statistics within central 5 mm [S: 2–5 mm (superior), I: 2–5 mm (inferior), minimum, maximum, SD (topographic variability), minimum–maximum], and the total corneal pachymetry maps were assessed by the Fourier-domain AS-OCT system and imaged by Scheimpflug imaging corneal topography for both groups.

## Results

For group A of keratoconic corneas, the attained results are as follows: the mean of epithelial thickness at the center was  $50.1 \pm 7.98 \mu\text{m}$ , superior  $56.01 \pm 6.98 \mu\text{m}$ , inferior  $48.73 \pm 5.97 \mu\text{m}$ , minimum  $39.95 \pm 9.11 \mu\text{m}$ , maximum  $62.92 \pm 8.85 \mu\text{m}$ , minimum–maximum  $-22.01 \pm 10.91 \mu\text{m}$ , and topographic variability  $6.9 \pm 4.2 \mu\text{m}$ . For group B of healthy control eyes, the mean of epithelial thickness at the center was  $52.71 \pm 3.71 \mu\text{m}$ , superior  $52.29 \pm 3.32 \mu\text{m}$ , inferior  $53.42 \pm 3.11 \mu\text{m}$ , minimum  $48.89 \pm 3.71 \mu\text{m}$ , maximum  $55.92 \pm 3.47 \mu\text{m}$ , minimum–maximum  $-6.3 \pm 3.51 \mu\text{m}$ , and topographic variability  $1.53 \pm 0.82 \mu\text{m}$ . All variables of epithelial thickness between the two groups are significant ( $P < 0.01$ ). In comparing the epithelial map of keratoconus (KCN) with the control group, the epithelium was found to be thicker at the maximum ( $+7 \mu\text{m}$ ) and superior location ( $+3.72 \mu\text{m}$ ), but thinner at the minimum ( $-8.94 \mu\text{m}$ ) and the inferior ( $-4.69 \mu\text{m}$ ) with highly significant differences in both minimum–maximum ( $-15.71$ ) and topographic variability ( $+5.37$ ). Moreover, in KCN, the point of minimum epithelial thickness was in accordance with the minimum point of the total corneal thickness and the maximum point of back elevation.

## Conclusion

The mapping for epithelial thickness utilizing AS-OCT could be a promising tool in KCN diagnosis.

## Keywords:

anterior segment-optical coherence tomography, epithelial thickness map, keratoconus, total corneal thickness

J Egypt Ophthalmol Soc 114:110–115

© 2021 Journal of the Egyptian Ophthalmological Society

2090-0686

## Introduction

The epithelium is one of the protective mechanisms of the cornea, and it comprises five to seven layers of cells with an increased ability of self-turnover in about 5–7 days [1,2]. Corneal epithelium thickness is  $\sim 50$ – $52 \mu\text{m}$  central and shares about 1.03 D and 0.85 of corneal refractive power over the central 2-mm and 3.6-mm-diameter zones, respectively [3]. The corneal epithelium is characterized by its great ability to reshape and modulate its thickness profile to afford an even, smooth, and regular optical surface masking the irregular stromal surface as in LASIK flap complication cases and early cone of keratoconus (KCN) [4,5].

KCN is a degenerative, noninflammatory ectatic corneal pathology where the cornea protrudes in a conical manner owing to the continuous progressive steepening, thinning of the corneal stroma, and its biomechanical stability reduction [6].

Corneal topography is the gold standard in the assessment of ectatic cornea [7]. There were reports of eyes with apparently normal topography but

This is an open access journal, and articles are distributed under the terms of the Creative Commons Attribution-NonCommercial-ShareAlike 4.0 License, which allows others to remix, tweak, and build upon the work non-commercially, as long as appropriate credit is given and the new creations are licensed under the identical terms.

developed post-LASIK ectasia [8,9]. One important issue before refractive procedures is detecting subclinical early-stage KCN, which promotes post-LASIK ectasia. Anterior segment-optical coherence tomography (AS-OCT) is noncontact, which provides high-quality, enhanced resolution two-dimensional image of the structure of a three-dimensional structure depending on an interferometer by comparing the delay and the difference of the intensity from the scattering of two distinct light beams [10,11].

The AS-OCT provides a perfect delineation of corneal surfaces, accurate assessment of the pachymetry (corneal thickness), and a precise evaluation of epithelial thickness of corneal mapping [12].

The study of the epithelium might deliver important clues in the early diagnosis of KCN. Some studies on KCN disclosed ongoing thinning of the stroma of the cone with an overlying confined area of a thinner epithelium surrounded by a donut of the thicker epithelium [10]. Several methods have been used to map the corneal epithelium [10,13,14].

In this study, our objective is to study the corneal epithelium thickness profile of KCN by epithelial mapping using AS-OCT for the future utility as an ancillary promising diagnostic tool for early detection and tracking of KCN patients.

---

## Patients and methods

This prospective case-control study was approved by the ethics committee of Benha University, Benha, Egypt, adhering to the tenets of the Declaration of Helsinki. Each participant was assigned an informed written consent.

The study involved 51 participants who were divided into two groups: study group A (50 keratoconic eyes of 26 patients) and control group B (50 eyes of 25 healthy controls of matched age and sex with group A). The exclusion criteria included signs or history of any corneal pathology (dystrophy, keratitis, and trauma), previous refractive or intraocular surgery, a late sign of KCN such as hydrops, and corneal scars (two eyes with corneal scars were excluded from the study).

Complete ophthalmic assessment of all participants included uncorrected visual acuity, best-corrected distance visual acuity, the manifest and full cycloplegic refraction, comprehensive slit-lamp examination, intraocular pressure measurement,

dilated fundus examination, and Scheimpflug imaging corneal tomography by the WaveLight Oculyzer (OčnaBolnicaProfesional, Trščanska, Zemun, Beograd).

In the study keratoconic eyes were diagnosed by clinical signs of KCN, as Rizzutti's sign (conical reflection on the nasal cornea by the lighting of the temporal cornea), Fleischer ring (deposition of iron in the epithelium near the base of the cone), scissoring of red reflex by retinoscope, and Vogt's striae and were confirmed by topographical characteristics for KCN as the power of central cornea more than or equal to 47.2 D, inferior superior power difference more than or equal to 1.4 (the mean of dioptric power of 5 inferior points minus the mean of dioptric power of 5 superior points, 3 mm from the corneal vertex), and the index of KISA% more than or equal to 100% (the product of four indices in the topography).

Corneal pachymetry and epithelial thickness maps were provided by the Fourier-domain AS-OCT system (Optovue, Fremont, California, USA) with an add-on lens (corneal adaptor module CAM-L mode: 6.0–2.0 mm) using a wavelength of 830 nm at a rate of 26 000 axial scans per second, of 5  $\mu\text{m}$  axial resolution, and of 15  $\mu\text{m}$  transverse resolution. Eight high-definition meridional B scans of 6 mm centered on the pupil were scanned in 0.31 s. Each B scan formed of 1024 A-scans and takes about 0.04 s. The examination is completed and repeated five times within 1.55 s. The analysis algorithm automatically displayed the corneal pachymetry and epithelial thickness maps over the area of 6 mm diameter, which is split into 17 sectors, formed of the pupil center disk (2-mm-diameter of 12.56  $\text{mm}^2$  area), the annulus between the 2–5 mm zones (divided into eight sectors, each of 8.24  $\text{mm}^2$  area), and the annulus of 5–6 mm zones (formed of octants, each of 4.32  $\text{mm}^2$  area). Epithelial software measures the superior epithelium (S): the value of mean thickness in the superior epithelium, the inferior epithelium (I): the value of mean thickness in the inferior epithelium, the minimum epithelium: the thickness of the thinnest point of the epithelium, the maximum epithelium: the thickness of the thickest point of the epithelium, minimum-maximum: the minimum epithelial thickness minus the maximum epithelial thickness, SD: the variance of all epithelial thicknesses within all 17 segments, central epithelial thickness (CET): the central point epithelium thickness.

The pachymetry map calculates the following: super nasal-infer temporal (SN-IT): the super nasal

thickness—the inferior temporal thickness; S-I: the mean superior corneal thickness—the mean inferior corneal thickness; minimum: the thickness of the thinnest corneal point; Location Y: the thinnest point location within the vertical meridian [(+) values for locations superior to the vertex of the cornea and (-) values for locations inferior to the corneal vertex]; minimum–median: the difference of thickness between the thinnest point and the median of all points; minimum–maximum: the thinnest thickness—the thickest corneal points; and CCT: the central corneal thickness.

### Statistical analysis

The data analysis was executed by the Statistical Program for Social Sciences, version 20 (SPSS Inc., Chicago, Illinois, USA).

Quantitative variables were mentioned as the mean and SD. Qualitative variables were presented in the form of number and percent. For comparison of parametric quantitative variables between two groups, Student's *t* test was done and *P* value less than 0.05 is taken into account to be significant.

### Results

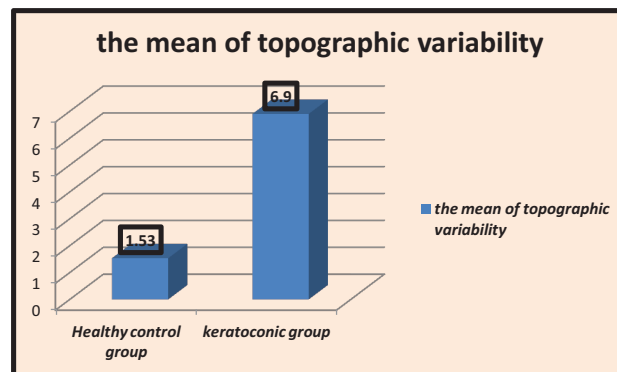
This study included 100 eyes of 51 patients and was divided into group A: 50 keratoconic eyes of 26 patients (14 men and 12 women) and group B: 50 eyes of 25 healthy individuals (15 males and 10 females). Concerning the patient's age, there was no statically significant difference ( $P=0.31$ ), as the mean age of the control group B was  $32.51 \pm 11.12$  and the mean age of group A was  $34.72 \pm 10.31$ .

All variables of epithelial thickness between two groups are significant, while the data are mentioned according to the significance.

Regarding topographic variability, there was a statistically significant difference in the mean of the SD ( $P < 0.00000003$ ) between the healthy control group B ( $1.53 \pm 0.82$ ) and the keratoconic group A ( $6.9 \pm 0.42$ ), as illustrated in Fig. 1. Inherently, in the minimum–maximum, there was a statistically significant difference of the mean of minimum–maximum epithelium ( $P < 0.00000005$ ) between the healthy control group B ( $-6.3 \pm 3.51$ ) and keratoconic group A ( $-22.01 \pm 10.91$ ) (Fig. 2).

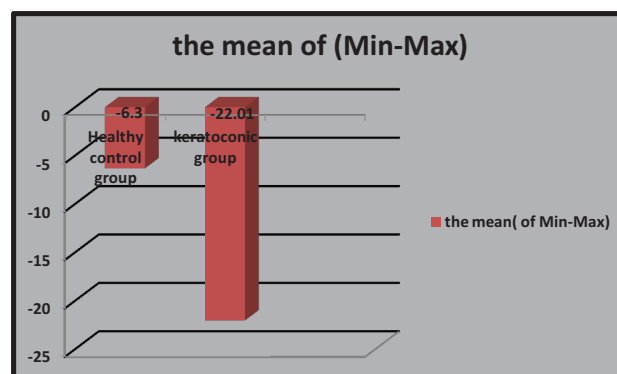
Accordingly, for the minimum epithelium, there was a statistically significant difference in the mean value of Min epi ( $P=0.000000005$ ): between healthy control

Figure 1



Mean values of topographic variability of the healthy control group and the keratoconic group.

Figure 2



Mean values of (minimum–maximum) of the healthy control group and the keratoconic group.

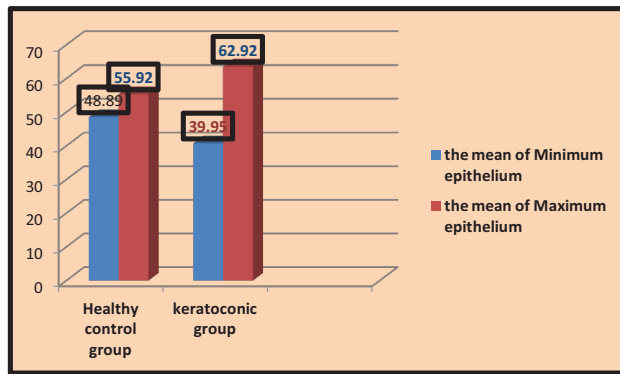
group B ( $48.89 \pm 3.71$ ) and keratoconic group A ( $39.95 \pm 9.11$ ). Furthermore, for the maximum epithelium, there was a statistically noteworthy variance of the mean of Max epi ( $P=0.0000003$ ) between healthy control group B ( $55.92 \pm 3.47$ ) and keratoconic group A ( $62.92 \pm 8.25$ , Fig. 3).

Regarding the inferior epithelium, a statistically significant difference is noticed in the mean of inferior epithelium ( $P=0.0000003$ ) between the healthy control group B ( $53.42 \pm 3.11$ ) and keratoconic group A ( $48.73 \pm 5.97$ ).

Subsequently, for the superior epithelium, there was a statistically significant difference of the mean of Sup-e: ( $P=0.001$ ) between the healthy control group B ( $52.29 \pm 3.32$ ) and the keratoconic group A ( $56.01 \pm 6.98$ ).

CET reveals a statistically significant difference in the mean of CET ( $P=0.03$ ) between the healthy control

Figure 3



Mean values of minimum epithelium and maximum epithelium of the healthy control group and the keratoconic group.

group B ( $52.71 \pm 3.08$ ) and the keratoconic group A ( $50.1 \pm 7.98$ ).

All variables of pachymetry map measures between two groups are significant.

Variables	Keratoconic group A (mean $\pm$ SD)	Healthy control B (mean $\pm$ SD)	P value
SN-IT	$65.92 \pm 35.2$	$17.42 \pm 12.85$	$<0.000$
S-I	$50.12 \pm 30.9$	$8.21 \pm 12.41$	$<0.000$
Minimum	$440 \pm 42.2$	$529 \pm 29.81$	$<0.000$
Y location	$-952 \pm 485$	$-157 \pm 289$	$<0.000$
Min-Med	$-51.39 \pm 20.36$	$-18.9 \pm 7.2$	$<0.000$
Minimum-maximum	$-110 \pm 49.92$	$-52.9 \pm 9.61$	$<0.000$

By studying the distribution pattern of the epithelial thickness in the keratoconic group, we revealed the point of minimum corneal epithelial thickness that was located inferotemporal to the corneal center (within the central, inferior temporal, inferior, and temporal octants) in the inferior half of the corneal epithelial map. This point of minimum epithelial thickness coincides with the minimum point of total corneal thickness and is in close relation to the maximum point of back elevation. In KCN, the corneal epithelium was thinner inferior more than superior with maximum thinning over the cone and surrounding with variable degrees of the thickened epithelium as depicted in Fig. 4. Conversely, in the control group, the corneal epithelium was superior thinner more than inferior.

In comparing the epithelial map of KCN to the control group, the epithelium was found to be thicker at the maximum ( $+7 \mu\text{m}$ ) and superior location ( $+3.72 \mu\text{m}$ ), but thinner at the minimum ( $-8.94 \mu\text{m}$ ) and the inferior ( $-4.69 \mu\text{m}$ ). That is

causing highly significant variances in both minimum-maximum ( $-15.71$ ) and topographic variability ( $+5.37$ ).

### Discussion

KCN is the most important ectatic corneal disorder, which prerequisites careful attention to be excluded before any refractive surgery to avoid the catastrophe of postoperative ectasia. Corneal tomography is still the cornerstone in the differentiation of the KCN from normal eyes [15].

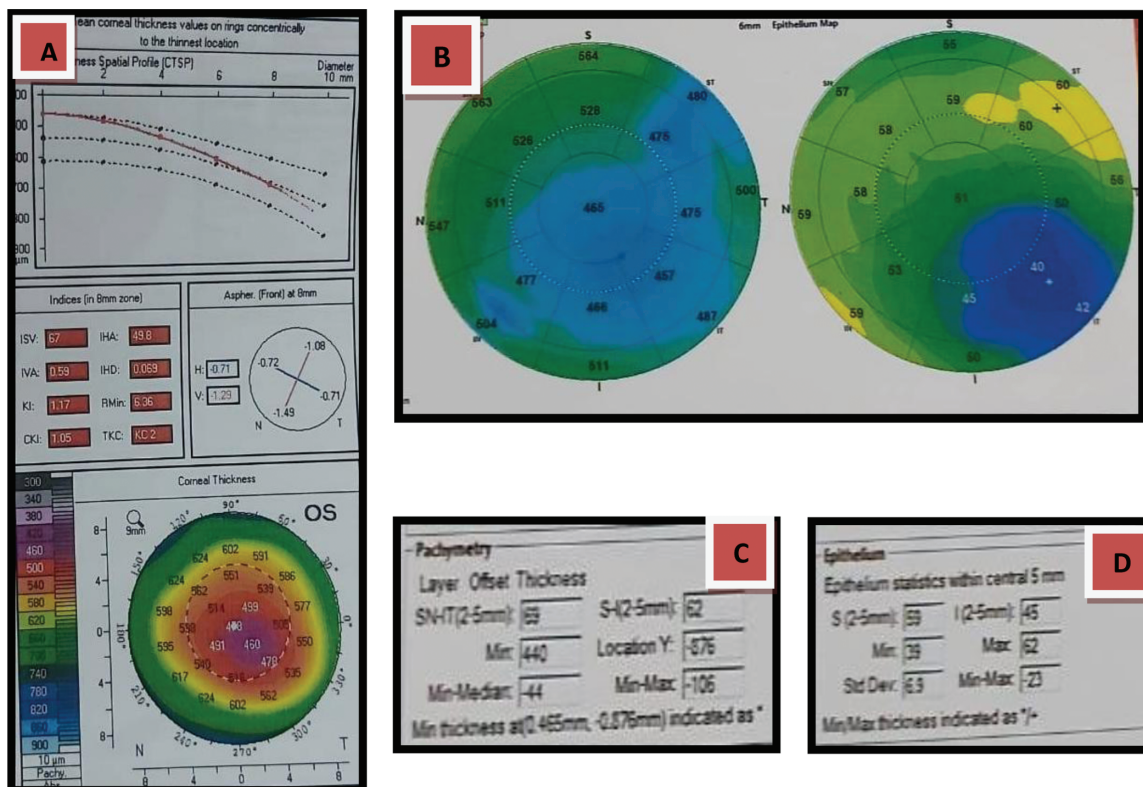
Suspicious parameters could occur in non-keratoconic corneas such as abnormally increased anterior or posterior elevation, focal steepening, and increased astigmatism [16]. Moreover, other factors may be misinterpreted as KCN, such as instability of tear film, misalignment, the patient's inability to fixate, corneal transparency loss, and contact lens warpage [7-9,17].

Corneal epithelium mapping by AS-OCT is a good supplementary screening tool to distinguish KCN from pseudo-KCN [18,19]. In KCN, there was epithelial thinning over the cone surrounded with a variable degree by an annulus of the thickened epithelium [10,18], whereas pseudo-KCN may be correlated to localized epithelial thickening [20].

That converges with our study, as in the keratoconic group, the mean corneal epithelium was thinner inferior ( $48.73 \pm 5.97$ ) more than superior ( $56.01 \pm 6.98$ ) by about 7.28 with maximum thinning over the cone and surrounding with variable degrees of thickened epithelium.

In our study, the distribution pattern of epithelial thickness in the keratoconic eyes is characterized by thicker epithelium superior ( $+3.72 \mu\text{m}$ ) and at the maximum ( $+7 \mu\text{m}$ ), thinner inferior ( $-4.69 \mu\text{m}$ ) and the minimum ( $-8.94 \mu\text{m}$ ), and highly significant differences in both minimum-maximum ( $-15.71$ ) and topographic variability ( $+5.37$ ) in comparison to the normal eye (all variables are significant  $P < 0.01$ ). In addition to the point of minimum corneal epithelium, the thickness was placed inferotemporal to the corneal center (within the central, inferotemporal, inferior, and temporal octants) in the inferior half of the corneal epithelial map and coincides with the minimum point total corneal thickness and in accordance with the maximum point of back elevation. The former studies of epithelial thickness profiles of normal corneas

Figure 4



Corneal thickness spatial profile, pentacam indices for keratoconus, and corneal thickness (pachymetry) by WaveLight Oculyzer II (A), maps for corneal epithelial thickness and total corneal pachymetry (B), variable values of corneal pachymetry (C), and variable values of the epithelial thickness (D) by Fourier-domain AS-OCT system RTVue. AS-OCT, anterior segment-optical coherence tomography.

disclosed that the superior meridian was thinner than the inferior cornea [21–23]. Our study matches that result as the mean of normal superior epithelial thickness was  $52.29 \pm 3.32$  and inferior epithelial thickness was  $(53.42 \pm 3.11)$  with a difference of about 1.13. This can be explained by several theories for epithelial thickness vertical asymmetry. First, Reinstein *et al.* [24] suggested that the friction effect of blinking abrades the epithelium of the cornea with a greater force applied on the superior meridian. Second, Du *et al.* [25] hypothesized that the upper eyelid exerts a constant force on the superior meridian causing long-term thinning. The upper eyelid covers a larger portion of the cornea in comparison to the lower eyelid in addition to gravity [10].

King-Smith *et al.* [26] supposed that pooling of the tear film in the inferior meridian may afford a false thick reading. However, the last suggestion rebutted by Reinstein *et al.* [27] by exploiting the VHF digital ultrasound with the immersion of the eye into normal saline and elimination of the role of the tear film from the analysis. Finally, the tear film may have less contact time with the superior

meridian and so less lubrication and more desquamation [28].

### Conclusion

The characteristic profile of epithelial thickness in KCN, mainly variability of topography (an increase of standard of deviation), the difference between the maximum and minimum thickness, and the distribution pattern of epithelial thickness offers an adjuvant complementary diagnostic tool in screening and diagnosis of KCN supporting the clinical, topographic, and Scheimpflug tomographic indicators in decision-making, especially in suspected subclinical early-stage cases before refractive surgery.

The limitation of our study is the small number of participants. Correlation of epithelial thickness with the severity of KCN and Pentacam indices will be assessed in future studies.

### Financial support and sponsorship

Nil.

## Conflicts of interest

There are no conflicts of interest.

## References

- Hogan MJ, Alvarado JA, Weddell JE. Histology of the human eye. Philadelphia, PA: Saunders Publishing; 1971.
- Hanna C, O'Brien JE. Cell production and migration in the epithelial layer of the cornea. *Jama Ophthalmology* 1960; 64:536–539.
- Simon G, Ren Q, Kervick GN, Parel JM. Optics of the corneal epithelium. *Refract Corneal Surg* 1993; 9:42–50.
- Reinstein DZ, Archer T. Combined Artemis very high-frequency digital ultrasound-assisted trans-epithelial phototherapeutic keratectomy and wavefront-guided treatment following multiple corneal refractive procedures. *J Cataract Refract Surg* 2006; 32:1870–1876.
- Reinstein DZ, Archer TJ, Silverman RH. Evaluation of irregular astigmatism with Artemis very high-frequency digital ultrasound scanning. In: Wang M, editor. *Irregular astigmatism: diagnosis and treatment*. Thorofare, NJ: SLACK Incorporated; 2007. pp. 29–42.
- Romero-Jimenez M, Santodomingo-Rubido J, Wolff-sohn JS. Keratoconus: a review. *Cont Lens Anterior Eye* 2010; 33:157–166.
- Hubbe R, Foulks G. The effect of poor fixation on computer-assisted topographic corneal analysis – pseudokeratoconus. *Ophthalmology* 1994; 101:1745–1748.
- Dursun D, Piniella A, Pflugfelder S. Pseudokeratoconus caused by rosacea. *Cornea* 2001; 20:668–669.
- Cheng HC, Lin KK, Chen YF, Hsiao CH. Pseudokeratoconus in a patient with soft contact lens-induced keratopathy: assessment with Orb scan I. *J Cataract Refract Surg* 2004; 30:925–928.
- Reinstein DZ, Archer TJ, Gobbe M. Corneal epithelial thickness profile in the diagnosis of keratoconus. *J Refract Surg* 2009; 25:604–610.
- Vidal S, Viqueira V, Mas D, Domenech B. Repeatability and reproducibility of corneal thickness using SOCT Copernicus HR. *Clin Exp Optom* 2013; 96:278–285.
- Li Y, Meisler DM, Tang M, Lu ATH, Thakrar V, Reiser BJ, et al. Keratoconus diagnosis with optical coherence tomography pachymetry mapping. *Ophthalmology* 2008; 115:2159–2166.
- Reinstein DZ, Silverman RH, Sutton HF, Coleman DJ. Very high-frequency ultrasound corneal analysis identifies anatomic correlates of optical complications of lamellar refractive surgery: anatomic diagnosis in lamellar surgery. *Ophthalmology* 1999; 106:474–482.
- Lovisolio CF, Mularoni A, Calossi A. Complications of refractive keratotomy. In: Alio J, Azar DT, editors. *Management of complications in refractive surgery*. Berlin, Germany: Springer-Verlag; 2008. pp. 197–224.
- Shajari M, Jaffary I, Herrmann K, Grunwald C, Steinwender G, Mayer W, Kohnen T. Early tomographic changes in the eyes of patients with keratoconus. *J Refract Surg* 2018; 34:254–259.
- Hick S, Laliberte J-F, Meunier J, Chagnon M, Brunette I. Effects of misalignment during corneal topography. *J Cataract Refract Surg* 2007; 33:1522–1529.
- Lang G, Holbach L, Schlotzer U. Pseudokeratoconus associated with Downs-Syndrome and posterior polymorphous corneal dystrophy. *Klin Monatsbl Augenheilkd* 1989; 195:95–99.
- Reinstein DZ, Gobbe M, Archer TJ, Silverman RH, Coleman DJ. Epithelial, stromal, and total corneal thickness in keratoconus: three-dimensional display with Artemis very-high frequency digital ultrasound. *J Refract Surg* 2010; 26:259–271.
- Kanellopoulos AJ, Asimellis G. OCT corneal epithelial topographic asymmetry as a sensitive diagnostic tool for early and advancing keratoconus. *Clin Ophthalmol (Auckland, NZ)* 2014; 8:2277–2287.
- Schallhorn JM, Tang M, Li Y, Louie DJ, Chamberlain W, Huang D. Distinguishing between contact lens warpage and ectasia: Usefulness of optical coherence tomography epithelial thickness mapping. *J Cataract Refract Surg* 2017; 43:60–66.
- Reinstein D, Archer T, Gobbe M, Silverman R, Coleman J. Epithelial thickness in the normal cornea: three-dimensional display with Artemis very high-frequency digital ultrasound. *J Refract Surg* 2008; 24:571–581.
- Kanellopoulos A, Asimellis G. In vivo three-dimensional corneal epithelium imaging in normal eyes by anterior segment optical coherence tomography: a clinical reference study. *Cornea* 2013; 32:1493–1498.
- Li Y, Tan O, Brass R, Jack L, Weiss J, David Huang D. Corneal epithelial thickness mapping by Fourier-domain optical tomography in normal and keratoconic eyes. *Ophthalmology* 2012; 119:2425–2433.
- Reinstein D, Silverman R, Trokel R, Coleman D. Corneal pachymetric topography. *Ophthalmology* 1994; 101:43–438.
- Du C, Wang J, Cui L, Shen M, Yuan Y. Vertical and horizontal corneal epithelial thickness profiles determined by ultrahigh-resolution optical coherence tomography. *Cornea* 2012; 31:1036–1043.
- King-Smith P, Fink B, Fogt N, Nichols K, Hill R, Wilson G. The thickness of the human precorneal tear film: evidence from reflection spectra. *Invest Ophthalmol Vis Sci* 2000; 41:3348–3359.
- Reinstein DZ, Archer TJ, Gobbe M, Silverman RH, Coleman DJ. Epithelial thickness in the normal cornea: three-dimensional display with Artemis very high-frequency digital ultrasound. *J Refract Surg* 2008; 24:571–581.
- Wang J, Aquavella J, Palakuru J, Chung S. Repeated measurements of dynamic tear distribution on the ocular surface after instillation of artificial tears. *Invest Ophthalmol Vis Sci* 2006; 47:3325–3329.