



ISSN NO. 2320-5407

Journal homepage: <http://www.journalijar.com>
Journal DOI: [10.21474/IJAR01](https://doi.org/10.21474/IJAR01)

INTERNATIONAL JOURNAL
OF ADVANCED RESEARCH

RESEARCH ARTICLE

ONE SITE VERSUS TWO SITE PHACOTRABECULECTOMY: RANDOMIZED CLINICAL TRIAL.

Soha Moussa Mohamed Eltohamy.

Manuscript Info**Manuscript History:**

Received: 11 April 2016
Final Accepted: 13 May 2016
Published Online: June 2016

Key words:

glaucoma, phacotrabeculectomy,
intraocular pressure

***Corresponding Author**

.....
**Soha moussa mohamed
eltohamy.**

Abstract

Purpose:- To compare one-site versus two-site phacotrabeculectomy in patients with visually significant cataract and primary open-angle glaucoma (POAG), with regard to achieve target intraocular pressure (IOP) and best visual acuity (VA).

Method:- Forty patients (40 eyes) with coexistence glaucoma and cataract were randomly assigned to undergo either a one-site (20 eyes) or a two-site (20 eyes) phacotrabeculectomy. One-site approach consisted of a standard superior phacotrabeculectomy, while two-site approach consisted of a clear cornea phacoemulsification and a separate superior trabeculectomy.

Results:- Mean preoperative intraocular pressure (IOP) in the one-site group was 22.05 mmHg (SD 1.6) and in the two-site group was 22.4 mmHg (SD 1.8) (P 0.4) using a mean of 2.6 (SD 0.5), 2.7(SD 0.4) antiglaucoma medication (AM), respectively (p 0.56). After thirty months of follow-up, the. Mean postoperative IOP significantly decreased in both groups compared to the preoperative level and was 14.2 mmHg (SD 1.06) in the one-site group and 13.5 mmHg (SD 1.19) in the two-site group (p 0.07), using a mean of 0.3 (SD 0.47), and 0.25 (SD 0.44) AM, respectively. Mean IOP and AM postoperatively were significantly less compared to preoperatively for each group (p < 0.05). AS regard postoperative IOP, the two sites has more reduction of IOP than one site but not statistically significant difference (p 0.07). AS regard postoperative AM two sites has less AM than one site to control IOP, but not statistically significant difference (p 0.94). AS regard postoperative best-corrected visual acuity (BCVA), the two site had better (BCVA) than the one site, but the difference was not statistically significant (P 0.97). There was less postoperative (induced) astigmatism in the two-site group and the difference was statistically significant ((p 0.01).

Conclusion:- Both one-site and two-site phacotrabeculectomy had similar results concerning final BCVA and IOP reduction. However, the two-site group had less induced astigmatism and a better postoperative IOP control with less required postoperative antiglaucoma medications compared to the one-site group.

.....
Copy Right, IJAR, 2016.. All rights reserved.

Introduction:-

The coexistence of visually significant cataract together with glaucoma is increasing with advancing age. In addition long standing miotic for glaucoma may lead to cataract and cataract may cause glaucoma. The best way to simultaneously manage these two conditions is a surgical challenge.

The primary angle-closure glaucoma (PACG) is caused by obstruction of aqueous fluid outflow through the iridocorneal angle causing elevation of the intraocular pressure (IOP) and optic nerve damage. So, IOP reduction is essential for the protection of visual function.¹

Phacoemulsification surgery produces less inflammation and fibrosis at the site of the incision than extracapsular cataract extraction.² The advantage of clear cornea approach is that the conjunctiva is intact with minimal distortion to the angle.³ Although, phacoemulsification is better than extracapsular cataract extraction for management of patients with visually significant cataract and glaucoma that is not adequately controlled with topical medication, but it may cause a significant short-term intraocular pressure (IOP) rise in the early postoperative period.⁴ If trabeculectomy is only done, the preexisting cataract will progress.⁵⁻⁸ Co-management of glaucoma and cataract by phacotrabeulectomy has the advantage of early visual rehabilitation and adequate control of glaucoma.

Phacotrabeulectomy consists of phacoemulsification and trabeculectomy which is performed through the same incision (one site) or two separate incisions (two sites)⁹.

If phacoemulsification incision separates from the trabeculectomy incision, it reduces postoperative scarring of the scleral flap and conjunctiva and improves the results of the filtration surgery¹⁰.

The purpose of this study was to compare prospectively the results of one site versus two-site phacotrabeulectomy as regard to VA, IOP, and glaucoma medication requirements.

Materials and methods:-

The current study is a prospective, randomized controlled trial conducted upon 40 cases who attended ophthalmology clinic of Benha University Hospital during a period of thirty months. Inclusion criteria were the presence of glaucoma and visually significant cataract. Visually significant cataract means a cataract that reduced the best-corrected visual acuity (BCVA) more than five lines in the Snellen chart. All patients had POAG with inadequate control of IOP (more than 21 mmHg) or requiring two or more antiglaucoma medications. All patients had typical glaucoma visual defect by automated perimetry (Humphrey perimetry threshold 30.2 or 24.2) and also progression of glaucoma damage (perimetry testing and C/D ratio evaluation).

Exclusion criteria were the presence of lens subluxation, neovascular glaucoma, advanced visual field loss, and/or excessive cupping of the disc or history of previous intraocular surgery, a history of uveitis, phacolytic or phacomorphic glaucoma, steroid-induced glaucoma, traumatic glaucoma or any ocular pathology that may affect final visual acuity. Patients were randomized into two groups: 1) Group I (n=20 eyes), who underwent one-site phacotrabeulectomy and 2) Group II (n=20 eyes), who underwent two-site phacotrabeulectomy. Written informed consent was obtained from all patients.

Procedures:-

One-site surgery:-

A superior fornix-based conjunctival flap was done by incising the conjunctiva at the limbus and dissecting posteriorly. Hemostasis is performed by wet field bipolar electrocautery mainly at the site of the scleral flap. A limited tenonectomy was made. A rectangular (3x4mm) partial (two-thirds)-thickness scleral flap was dissected until clear cornea. Then a paracentesis was made by MVR, followed by injection of a viscoelastic. A valved entry into the anterior chamber under the scleral flap was made using a 3.2-mm blade keratome. Phacoemulsification (capsulorhexis –hydrodissection and hydrodelimitation –emulsification of nucleus –irrigation aspiration of cortical matter) then was performed. A foldable acrylic intraocular lens (IOL) was implanted into the capsular bag. Then aspiration of all viscoelastic and injection of acetylcholine to constrict the pupil. No antimetabolites were used. A trabeculectomy (1.5x2) was performed with a knife and Vannas scissors. The iris is pulled out and peripheral iridectomy was performed. The scleral flap was closed with two 10-0 nylon sutures at the corners, and the conjunctival flap was sutured with a mattress-type 10-0 nylon suture. Injection of a balanced salt solution through the paracentesis to deep anterior chamber, to detect leakage and test the function of the bleb. A subconjunctival injection of 0.25cc dexamethasone 1mg/ml and 0.25cc gentamicin 40mg/ml in lower fornix.

Two-site surgery:-

The two-site procedure means that separation of trabeculectomy incision from that phacoemulsification. that of consisted of trabeculectomy (which is done superiorly) and phacoemulsification(which is performed temporally). A fornix-based conjunctival flap was fashioned superonasally. Minimal electrocautery (to reduce postoperative scaring) and a limited tenonectomy was performed. A rectangular (3x4mm) partial-thickness scleral flap was performed, without the use of antimetabolites. A phacoemulsification (capsulorhexis –hydrodissection and hydrodelimitation –phacoemulsification of nucleus –irrigation aspiration of cortical matter) through a temporal clear corneal incision was performed, and a foldable acrylic posterior chamber IOL was inserted into the capsular bag . then dissection of scleral flap was advanced into clear cornea. The anterior chamber was entered with a 3.2-mm blade keratome The trabeculectomy was subsequently performed with a knife and Vannas scissors, followed by a peripheral iridectomy. The scleral flap was then sutured with two 10-0 nylon sutures. the conjunctival flap was sutured with 8-0 vicryl suture. Injection of a balanced salt solution through the paracentesis to deep anterior chamber, to detect leakage and test the function of the bleb. A subconjunctival injection of 0.25cc dexamethason 1mg/ml and 0.25cc gentamicin 40mg/ml in lower fornix.

All patients received the same postoperative regimen :A topical antibiotic were used three times daily for two weeks. Topical corticosteroids were given three times daily for the first two weeks, then reduced to two times daily for next a week and lastly one time for a weak were tapered slowly. patient data.

Patient data

Preoperative:- history of name, age, sex , the number of preoperative antiglaucoma medications, systemic diseases and history of laser and surgical operations.compelte ophthalmic examination included BCVA measurement, IOP measurement by Goldmann applanation tonometry and detection of any other ocular pathology that may affect final visual acuity.**Operative:-** include date of operation, surgical procedure (one-site or two-site phacotrabeulectomy), and the presence of any operative complications.**postoperative** : IOP was measured 24 hours after surgery, and then on the third day, one week, one month, and then every 3 months. If it was above 20 mmHg , an antiglaucoma medication was given. BCVA was measured at one month and then every 3 months . the presence of any postoperative complications and the number of antiglaucoma medications were recorded.

SPSS version 14.0 (SPSS Inc., Chicago, IL) was used for the statistical analysis and p value less than 0.05 was considered as statistical significant.

Results

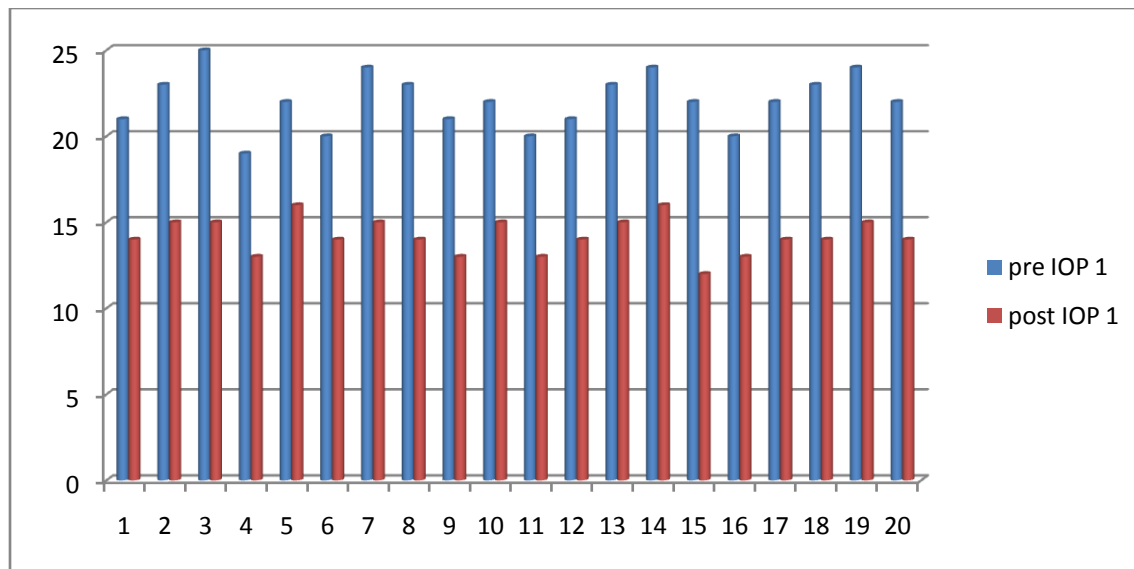
This study was conducted upon 40 eyes of 40 patients who had visual significant cataract and primary open angle glaucoma.the patient fulfilled the inclusion criteria. the cases were dividing randomly into two groups. Group I :20 patients (14 male 70% and 6 female 30%) who underwent one site phacotrabeulectomy. Group II: 20 patients (12 male 60% and 8 female 40%), who underwent two-site phacotrabeulectomy. There was no statistically significant difference between the two groups as regard to age, sex , preoperative IOP, and number o fpreoperative antiglaucomaus medications and preoperative BCVA because p value is more than 0.05 as shown in Table 1 .

Table 1:- preoperative data of patients.

	Group I	Group II	P value
Age	60 (SD 1.3)	60.22 (SD 1.8)	0.62
Sex	14 Male ,6 female	12 male ,8 female	
Mean preoperative IOP	22.05 mmHg (SD 1.6)	22.4 mmHg (SD 1.8)	0.4
The mean of antiglaucomatus medication preoperatively	2.6 (SD 0.5)	2.7 (SD 0.4)	0.56
BCVA (log MAR)preoperatively	0.822 (SD 0.18)	0.833 (SD 0.18)	0.68

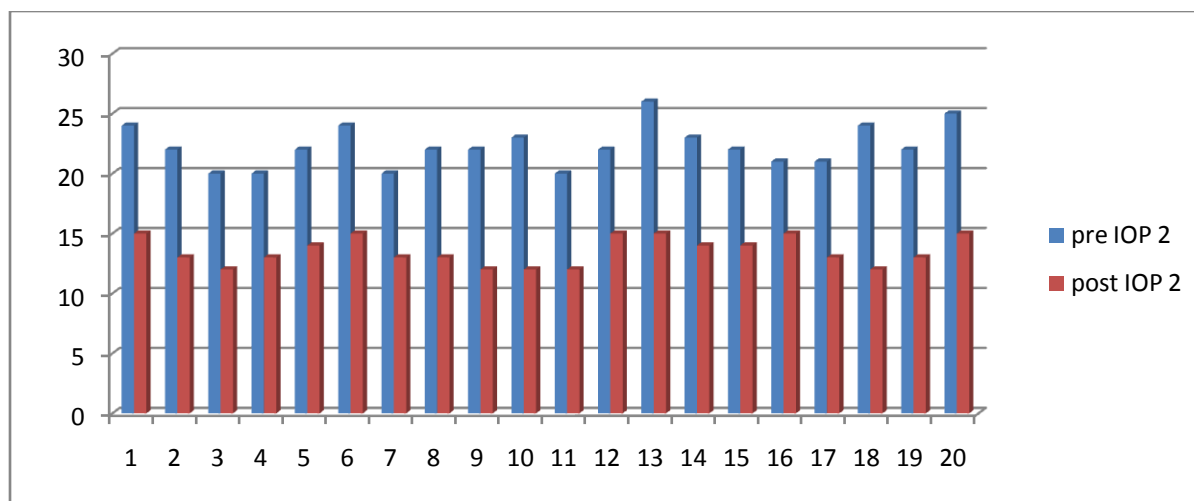
There was statistically significant reduction in the intraocular pressure as mean IOP was reduced from 22.05 mmHg (SD 1.6) preoperatively to 14.2 mmHg (SD 1.06) postoperatively in the one-site group (p 0.00008) and from 22.4 mmHg (SD 1.8) preoperatively to 13.5 mmHg (SD 1.19) postoperatively in the two-site group (p 0.00008). So the

two-site group had more reduction in IOP than one-site group , but the difference between them was not statistically significant (p 0.074).



The number of patient.

Figure 1:- the pre- and postoperative intraocular pressure (IOP) for each eye, in the one-site group.



The number of patients.

Figure 2:- The pre- and postoperative intraocular pressure (IOP) for each eye, in the two-site group.

As regard to antiglaucomatus medications , their mean was reduced from 2.6 (0.5) preoperatively to 0.3 (SD 0.47), postoperatively in the one site group group (p 0.00008) and from 2.7(0.4) preoperatively to The 0.25 (SD 0.44) postoperatively in the two-site group (p 0.00008).So there is statistically significant reduction of antiglaucomatus medications in both groups (p < 0.05). Although of the two-site group needed less antiglaucomatus medications than one site group group.but there was no statistically significant difference between them (p 0.94).

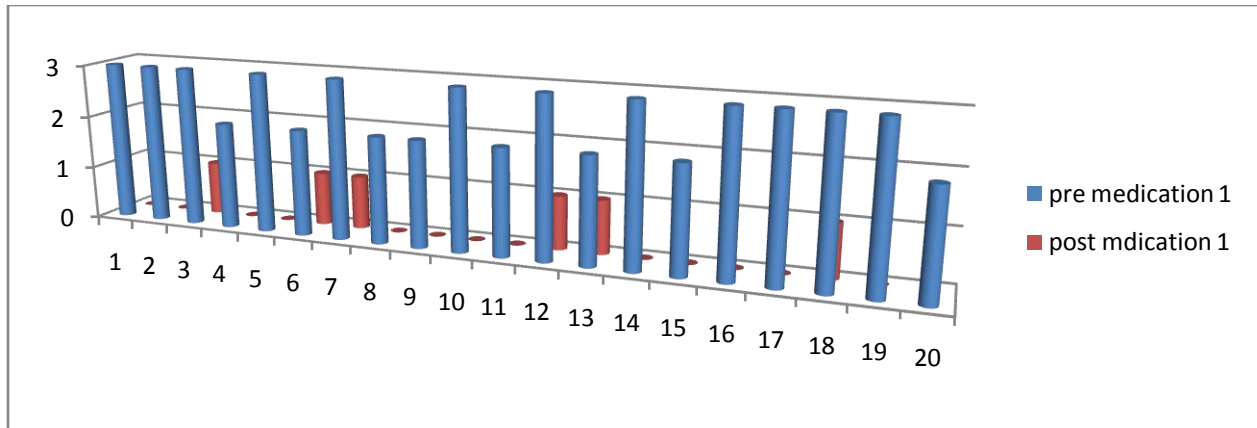


Figure 3:- Number of pre- and postoperative glaucoma medications for each eye, in the one-site group.

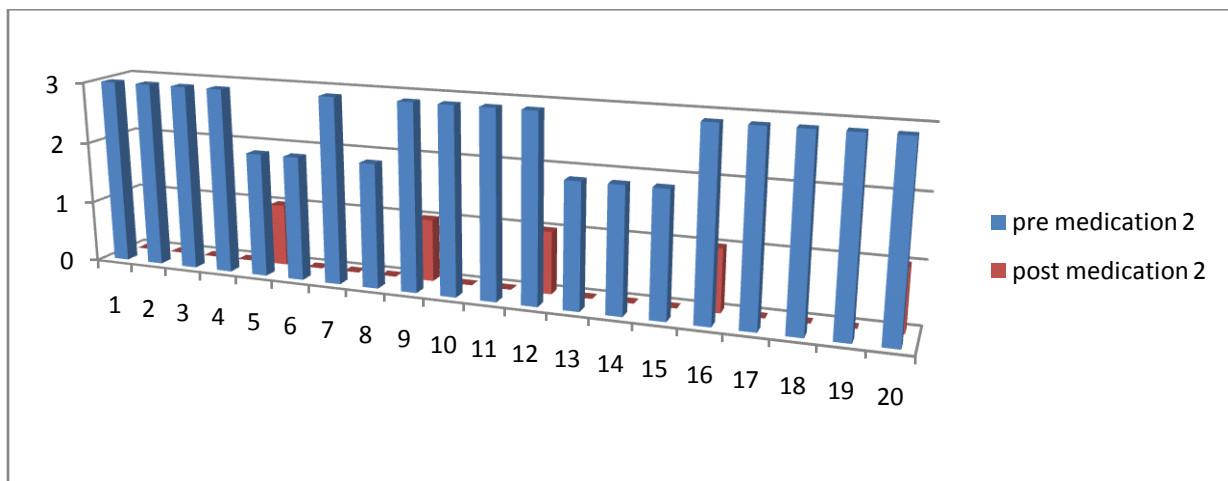


Figure 4:- Number of pre- and postoperative glaucoma medications for each eye, in the two-site group.

AS regard to postoperative best-corrected visual acuity (BCVA),there was improvement from 0.82 (SD 0.18) logMAR preoperatively to 0.15 (SD 0.11) logMAR postoperatively in the one site group (P 0.000088),and from 0.83 (SD 0.18)) logMAR preoperatively to 0.14 (SD 0.11) logMAR postoperatively in the two site group (P 0.000088).Although the two site had better (BCVA) than the one site, but the difference was not statistically significant (P 0.97).

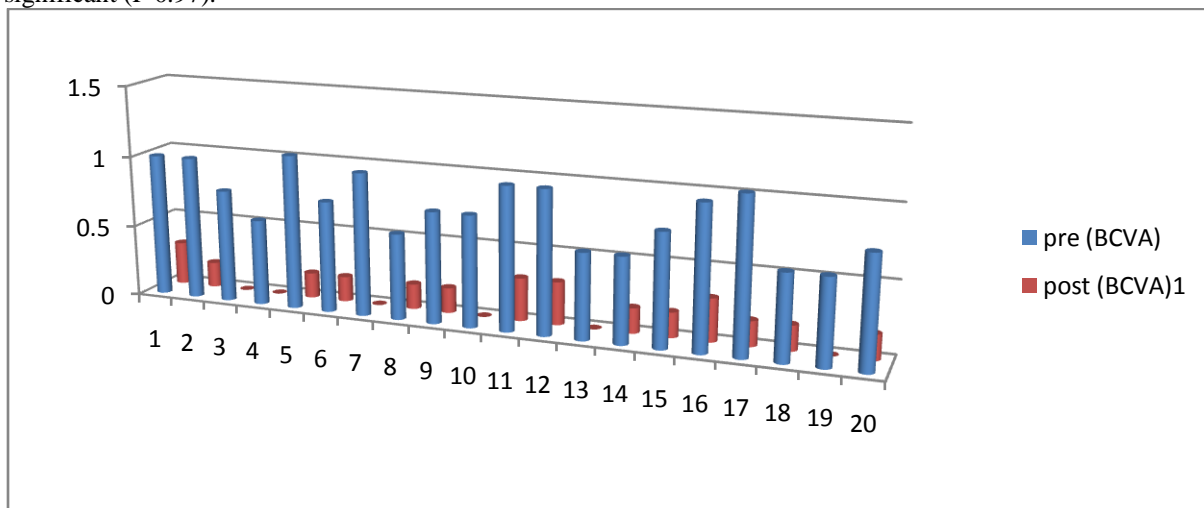


Figure 5:- the pre- and postoperative best-corrected visual acuity (BCVA) for each eye, in the one-site group.

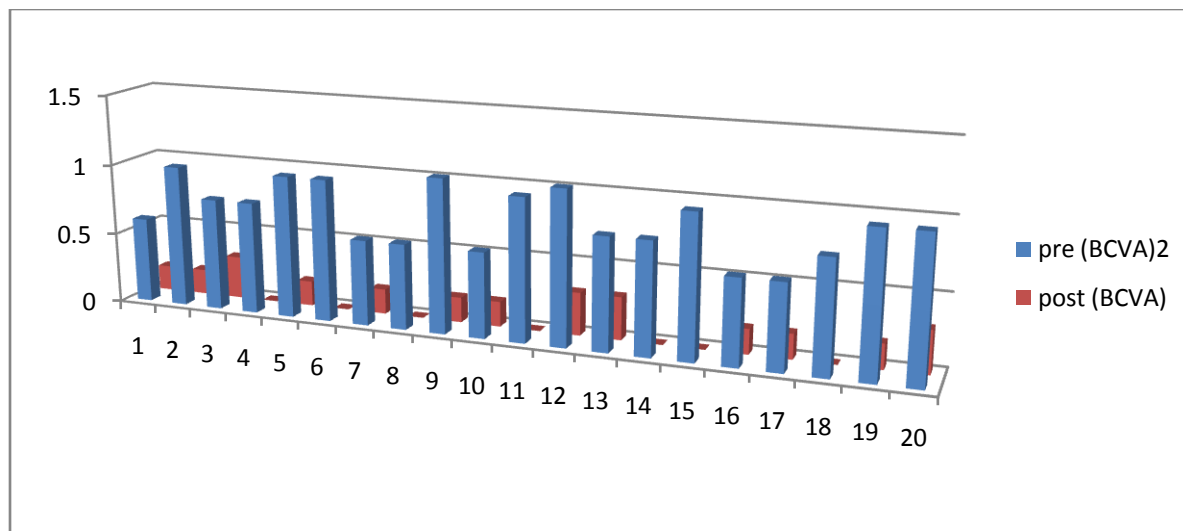
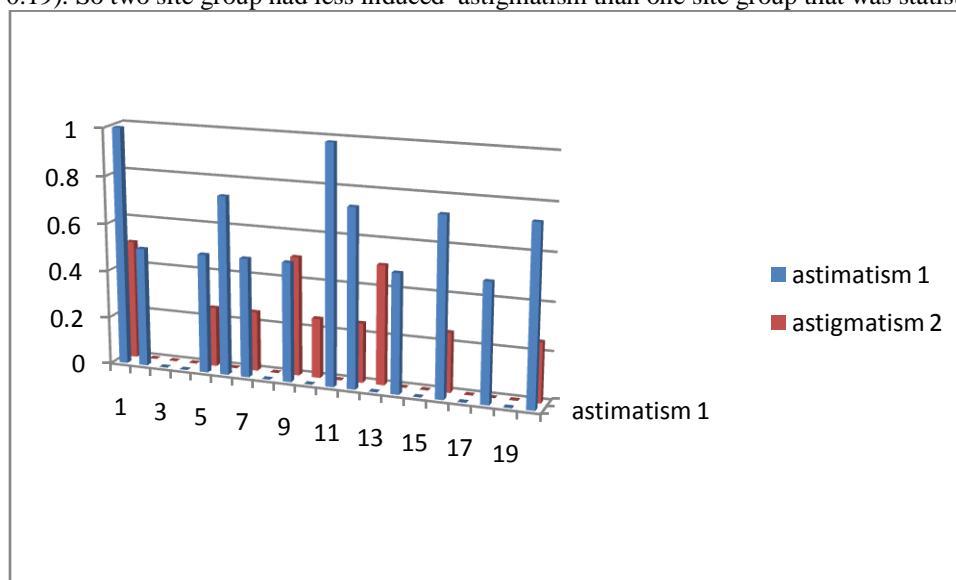


Figure 6:- the pre- and postoperative best-corrected visual acuity (BCVA) for each eye, in the one-site group.

AS regard to postoperative astigmatism , the one site group had 0.4D (SD .36) while two site group had 0.15D (SD 0.19). So two site group had less induced astigmatism than one site group that was statistically significant (P 0.01).



There was no intraoperative or postoperative complication apart from one case of shallow anterior chamber that is controlled medically in one site group.

Table 2:- the post operative data of Group I and Group II.

	Group I	Group II	P value
Mean postoperative IOP	14.2 mmHg (SD 1.06)	13.5 mmHg (SD 1.19)	P 0.074
The mean of antiglaucomatus medication postoperatively	0.3 (SD 0.47),	0.25 (SD 0.44)	p 0.94
BCVA (log MAR)postoperatively	0.15 (SD 0.11)	to 0.14 (SD 0.11)	P 0.97
postoperative astigmatism	0.4D (SD .36)	0.15D (SD 0.19).	P 0.01

Discussion:-

The incidence of presence of cataract together with glaucoma is increasing as the life expectancy increases. Challenge of managing of coexisting cataract and glaucoma becomes more frequent. the cataract surgery alone can be done when the patient had significant cataract and early mild glaucoma controlled with only one medication.¹¹ the main indication of combined surgery is the patient had significant cataract and uncontrolled glaucoma or poor compliance.¹² The advantages of phacotrabeculectomy are early visual rehabilitation ,adequate long term controll of IOP and save the time and effort.¹³

The decision is to perform combined phacotrabeculectomy through one or two sites. The two-site approach has advantage of less manipulation of the conjunctiva and extraction of cataract easily while one -site approach has advantage of less number of incisions.¹⁴

The main concern in this study is to compare one-site versus two-site fornix-based phacotrabeculectomy without the use of antimetabolites in reducing IOP and the need of antiglaucoma medications .The result of this study is that the two-site approach is more effective in reducing IOP and the need for supplemental antiglaucoma medications than one -site approach ,but the difference is not statistical significant ($P > 0.05$). And both surgical strategies succeeded in decreasing IOP and the need for antiglaucoma medications and their effects were statistical significant ($P < 0.05$).

the one-site technique was less effective and required the more medications to obtain the same level of IOP as the two-site technique. This can be due to increased manipulation of the conjunctival and scleral flaps inducig fibrosis.¹⁵ In addition to the local increase in temperature at the trabeculectomy site and at the scleral flap caused by the production of heat by the phacoemulsification probe is another possible factor contributing to decrease the efficacy of the one-site technique.

Previous studies supported that there was no statistically significant difference in postoperative IOP between one- and two-site phacotrabeculectomy¹⁶⁻¹⁸, although a recent meta-analysis of randomized controlled trials concluded that the two-site phacotrabeculectomy is superior to one-site phacotrabeculectomy in reducing IOP.¹⁹

Two studies comparing one- versus two-site phacotrabeculectomy found that the one-site group needed significantly more medications than the two-site group.^{13,20} In contrast, two other prospective studies and one retrospective study suggested that there was no statistical difference in the postoperative mean number of glaucoma medications in one- versus two-site phacotrabeculectom.^{14,21,2}

There was significant improvement in the postoperative best-corrected visual acuity (BCVA) in both one site and two groups ($P > 0.05$). Although two site group had better BCVA than one site group , but the difference was not statistically significant ($P 0.97$). two site group had less induced astigmatism than one site group that was statistically significant ($P 0.01$).

studies founded that a scleral tunnel produces less astigmatism compared to a clear corneal incision in cataract surgery.²³ Other authors founded that an incision at the 12 o'clock position produces more astigmatism compared to a temporal incision.²⁴ So less astigmatic effect of the scleral tunnel was outweighed by the astigmatism-inducing effect of an incision at the 12 o'clock position in addition to more manipulations through the scleral tunnel can lead to that one site group has more induced astigmatism than one site group .

There was no intraoperative or postoperative complication apart from one case of shallow anterior chamber that is controlled medically in one site group.

References:-

1. Gazzard G, Foster PJ, Devereux JG, Oen F, Chew P, Khaw PT, et al. Intraocular pressure and visual field loss in primary angle closure and primary open angle glaucomas. *Br J Ophthalmol* 2003; 87: 720-725.
2. Beckers HJM, de Kroon KE, Nuijts RMMA, Webers CAB. Phacotrabeculectomy. *Doc Ophthalmol*. 2000;100:43-47.
3. Tennen DG, Masket S. Short- and long-term effect of clear corneal incisions on intraocular pressure. *J Cataract Refract Surg*. 1996;22:568-570.
4. Tezel G, Kolker AE, Kass MA, Wax MB. Comparative results of combined procedures for glaucoma and cataract: I. Extracapsular cataract extraction versus phacoemulsification and foldable versus rigid intraocular lenses. *Ophthalmic Surg Lasers*. 1997;28:539-550.
5. Krupin T, Feitl ME, Bishop KI. Postoperative intraocular pressure rise in open-angle glaucoma patients after cataract or combined cataract-filtration surgery. *Ophthalmology*. 1989;96:579-584.
6. Obstbaum SA. Glaucoma and intraocular lens implantation. *J Cataract Refract Surg*. 1986;12:257-261.
7. Gimbel HV, Meyer D, DeBroff BM, Roux CW, Ferensowicz M. Intraocular pressure response to combined phacoemulsification and trabeculectomy ab externo versus phacoemulsification alone in primary open-angle glaucoma. *J Cataract Refract Surg*. 1995;21:653-660.
8. Suzuki R, Kuroki S, Fujiwara N. Ten-year follow-up of intraocular pressure after phacoemulsification and aspiration with intraocular lens implantation performed by the same surgeon. *Ophthalmologica*. 1997;211:79-83.
9. Bradford J, Shingleton M, Richard S, et al. Comparison of 1-site versus 2-site phacotrabeculectomy. *J Cataract Refract Surg*. 2006;32:799-80.
10. Vass C, Menapace R. Surgical strategies in patients with combined cataract and glaucoma. *Curr Opin Ophthalmol*. 2004;15:61-66.
11. Heffelfinger BL, Berman MN, Krupin T, Rosenberg LF, Ruderman JM. Surgical management of coexisting glaucoma and cataract. *Ophthalmol Clin North Am*. 2000;13(3) :545-52. Review
12. Chen H, Ge J, Lu X, Lu F. The clinical analysis of 260 combined surgery of glaucoma and cataract. *Yan Ke Xue Bao* 2000;16(2) :102-5.
13. Wyse T, Meyer M, Ruderman JM, et al. Combined phacotrabeculectomy and phacoemulsification: a one-site v two-site approach. *Am J Ophthalmol*. 1998;125:334-339.
14. Park HJ, Weitzman M, Caprioli J, el Sayyad F, Helal M, el-Maghraby A, Khalil M, el-Hamzaway H. Onsite versus 2-site phacotrabeculectomy: a randomized study. *J Cataract Refract Surg*. 1999;25:77-82.
15. Weitzman M, Caprioli J. Temporal phacoemulsification combined with separate-incision trabeculectomy. *Ophthalmic Surg Lasers*. 1995;26: 271-273
16. Buys YM, Chipman ML, Zack B, Rootman DS, Slomovic AR, Trope GE. Prospective randomized comparison of one- versus twosite phacotrabeculectomy two-year results. *Ophthalmology*. 2008;115: 1130-1133.
17. Bagli E, Gartzios C, Asproudis I, Kitsos G. Comparison of one-site versus two-site phacotrabeculectomy without the use of antimetabolites intraoperatively in patients with pseudoexfoliation glaucoma and primary open-angle glaucoma. *Clin Ophthalmol*. 2009;3:297-305.4
18. Cotran PR, Roh S, McGwin G. Randomized comparison of 1-site and 2-site phacotrabeculectomy with 3-year follow-up. *Ophthalmology*. 2008;115:447-454.
19. Liu HN, Chen XL, Li X, Nie QZ, Zhu Y. Efficacy and tolerability of one-site versus two-site phacotrabeculectomy: a meta-analysis of randomized controlled clinical trials. *Chin Med J*. 2010;123:2111-2115
20. Rossetti L, Bucci L, Miglior S, et al. Temporal corneal phacoemulsification combined with separate-incision superior trabeculectomy vs standard phacotrabeculectomy; a comparative study. *Acta Ophthalmol Scand Suppl*. 1997;224:39.
21. Borggreffe J, Lieb W, Grehn F. A prospective randomized comparison of two techniques of combined cataract-glaucoma surgery. *Graefes Arch Clin Exp Ophthalmol*. 1999;237:887-892.
22. el Sayyad F, Helal M, El-Maghraby A, et al. Comparison of 1-site versus 2-site phacotrabeculectomy. *J Cataract Refract Surg*. 2006;32:799-802.
23. Vyas AV, Bacon PJ, Persival SP. Phacotrabeculectomy: comparison of results from 3.5- and 5.2-mm incisions. *Ophthalmic Surg Lasers*. 1998;29: 227-233
24. Cagini C, Murdolo P, Gallai R. Long-term results of one-site phacotrabeculectomy. *Acta Ophthalmol Scand*. 2003;81:233-236.22