



Mucopolysaccharidosis



Scientific data belongs to Prof. Dr. Naglaa Azab
(Head of Medical Biochemistry & Molecular Biology Department)

Presentation prepared by
Dr. Shuzan Ali Mohammed
Assist. Prof. of
Medical Biochemistry & Molecular Biology

<https://drive.google.com/file/d/19fzQ-YAUU2sd7bYDdW6ZG-R1OSAovqvK/view?usp=sharing>

Shuzan Ali 2023/2024

Mucopolysaccharidosis

Def.

A group of inherited inborn errors of metabolism, progressive lysosomal storage disorders (1:25000 live births).

Age of onset:

initially normal development with the abnormality appear in infancy or later in childhood.



Incidence of subtypes:

- The most common subtype is MPS III, followed by MPS I and MPS II

Inheritance:

- All MPS are autosomal recessive (AR) except MPS II (Hunter syndrome) which is X-linked (occurs in males only).



Cause and pathogenesis

- **Mutation** in the genes coding for the lysosomal enzymes that degrade GAG →
- **Variable expression** of mutated enzymes →
- **Variable residual** enzyme activity
(complete absence, deficiency or malfunction) →
- **Accumulation of GAG** in lysosomes interfering with cell function causing permanent progressive damage in cells, tissues and organs →
- **Variable severity of disease** with characteristic pattern of clinical, radiologic and biochemical abnormalities



N.B.

- Within this pattern, specific diseases can be recognized resulting from intracellular accumulation of different degradation products.

As a general role,

- Impaired degradation of heparan sulfate is more closely associated with mental deficiency.
- Impaired degradation of dermatan sulphate, chondroitin sulfate, & keratan sulfate is more closely associated with mesenchymal abnormalities.
- Variable severity of disease is manifest e.g. in MPS I;
 - homozygous or double heterozygous non-sense mutation (stop codon) → severe form of Hurler disease.
 - mis-sense mutation → preserve some residual enzyme activity (mild form of Hurler disease).



Clinical abnormality of MPS:

1. Physical features:

- Coarse facial features (due to storage of GAGs in soft tissues of the face)
- Skeletal abnormalities: early, prominent feature
- Most patients show progressive change in size and shape of bone, involving almost all bones as:
 - short stature with disproportionate short trunk in all MPS except MPS IS
 - Spine deformity (kyphosis, scoliosis & lordosis)
- Joint stiffness is common in MPS except MPS IV (hyperlax)



Clinical abnormality of MPS:

2. Neurologic: intellectual changes & behaviour disability
3. Hepato-splenomegaly
4. Respiratory: Obstructive airway disease with frequent infections
5. Cardiovascular: valve disease, angina, heart failure
6. Eye: corneal clouding, glaucoma, retinal degeneration
7. Ear: deafness



Generally the patients present in one of three ways:

1. Dysmorphic syndrome (MPS IH, MPS II, MPS VI)
2. Learning difficulties, behavioral disturbance, dementia and mild somatic abnormalities (MPS III)
3. Severe bone dysplasia (MPS IV)

N.B.

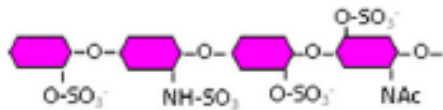
1. Heparan sulfate degradation is impaired in MPS types I-H, I-H/S, II, III & VII → Show mental retardation, however mild MPS II may show no mental deficiency.

2. Absence of corneal opacity in MPS II & IX & not common in MPS III & Fine in MPS IV

3. MPS VII presents commonly at birth with hydrops fetalis (severe fatal disease usually die at birth)



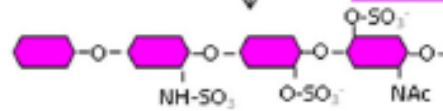
HS



Iduronate sulphatase



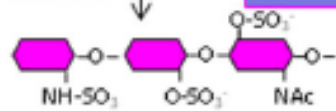
MPS II



Iduronidase



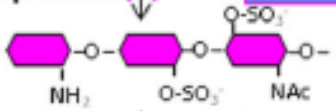
MPS I



Heparan sulphatase



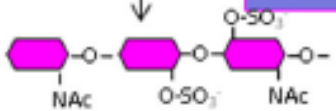
MPS III A



Acetyl transferase



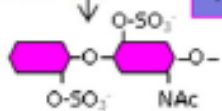
MPS III C



N Ac glucosaminidase



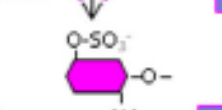
MPS III B



β-glucuronidase



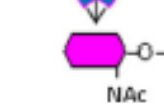
MPS VII



N Ac glucosamine sulphatase

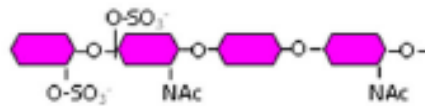


MPS III D



Stepwise degradation of the main glycosaminoglycan chains

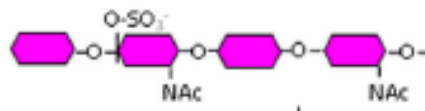
DS



Iduronate sulphatase



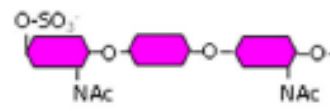
MPS II



Iduronidase



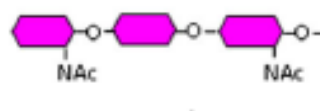
MPS I



N Ac galactosamine sulphatase



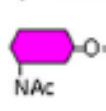
MPS VI



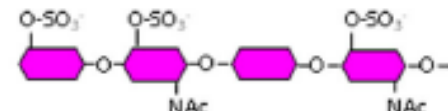
β-glucuronidase



MPS VII



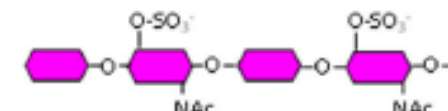
KS



Galactose 6-sulphatase



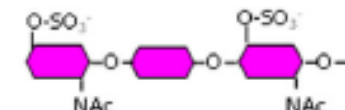
MPS IV A



β-galactosidase



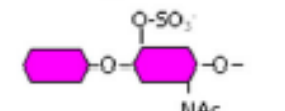
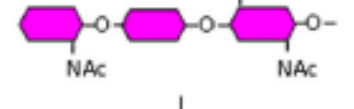
MPS IV B



N Ac glucosamine sulphatase



MPS III D



Subtypes & Disease		Enzyme defect	Affected GAGs & Urinary MPS
<u>MPS I</u>		α -L-iduronidase	DS & HS
MPS I-H (Hurler)		Severe	
MPS I-H/S (Hurler/Scheie)		Moderate	
MPS I-S (V) (Scheie)		Mild (dermatan sulfate only in urine)	DS
MPS II (Hunter)		Iduronate-2-sulfatase	DS & HS
MPS III (Sanfillipo)	A	Heparan-Sulfate sulfatase	HS
	B	α -N-acetyl Glucosaminidase	
	C	Acetyl transferase	
	D	N- acetyl glucosamine 6- sulfatase	
MPS <u>IV</u> (Morquio)	<u>A</u>	N-acetyl galactosamine <u>6</u> - sulfatase	KS & CS
	B	β -galactosidase.	KS
MPS <u>VI</u> (Maroteaux-Lamy)		N- acetyl galactosamine <u>4</u> - sulfatase	DS
MPS VII (Sly)		β -Glucuronidase	DS, HS & CS
MPS IX		Hyaluronidase 1	Hyaluronic acid (\uparrow in plasma)

DS: dermatan sulphate, HS: heparin sulfate,
KS: keratan sulfate & CS: chondroitin sulfate



Laboratory diagnosis

1. Urinary GAG analysis (24 hour urine):

Quantitative assay for the total amount of GAG;
elevated level in age-matched normal subjects

Qualitative assay (determine type of elevated GAG)

2. Enzyme activity assay in WBCs, fibroblast or serum

3. Molecular genetic testing for mutation in the genes coding for the defective enzyme

4. Increased plasma hyaluronan level in type IX

Other tests that may be done:

5. Prenatal diagnosis using amniotic fluid cells (Amniocentesis) or chorionic villus biopsy.

6. Genetic counselling



N.B.

- **Urinary GAG can be used for disease monitoring**
- When a sibling of MPS patient is identified, the other undiagnosed siblings should undergo the same clinical history & laboratory testing.

Treatment:

1. Enzyme replacement therapy: used in MPS I & II but can not prevent neurological damage
2. **Bone marrow & cord blood transplantation: limited success (macrophage enzymes degrade GAG)**
3. Treatment of various clinical manifestations



Mucopolysaccharidosis Case I

A seven year old boy is brought to the physician with severe mental retardation, on asking the mother; several members of the mother's and father's family had mental retardation. The mother also noticed that this child is very active, restless and frequently get into troubles in his school.

On examination; the boy appeared restless with delayed incomprehensive speech, coarse facial features and normal other examination. The lab tests showed elevated heparan sulphate.

Questions

- What is the most likely diagnosis?
- What is the inheritance pattern of this disorder?
- What are the other causes of MPS?



Answers

1. MPS III (Sanfillipo syndrome)
2. Autosomal recessive (AR)
3. **Write all other types of MPS;
Hurler (MPS I), Hunter (MPS II), Morquio (IV), Maroteaux-Lamy (VI), Sly (VII), hyaluronidase deficiency (IX)**

* The first explanation for diagnosis;

MPS present in one of three ways:

1. As a dysmorphic syndrome (e.g. MPS I, MPS II, MPS VI).
2. With learning difficulties, behavioral disturbance and dementia and mild somatic abnormalities (MPS III)
3. As a severe bone dysplasia (MPS IV)

* The second explanation presence of heparan sulfate in urine (the only metabolite present)



Case 2:

An infant presented with corneal clouding. His urine examination showed dermatan sulphate and heparan sulphate. He was diagnosed as Hurler syndrome.

- One of the following enzymes has decreased activity to confirm the suspected diagnosis:
 - a. α -L-iduronidase
 - b. α -glucuronidase
 - c. Glycosyl transferase
 - d. Iduronte sulfatase

Answer:

- a. α -L-iduronidase



Case 3

- A fifteen month old white female was brought to the paediatrician because of upper respiratory tract infection. On examination; the girl was noticed to have short stature, some corneal clouding, coarse facial features, some hearing loss, developmental delay. It was suspected to has MPS. Which of the following is the least likely to affect her:
 - a. Hurler syndrome (MPS I)
 - b. Hunter syndrome (MPS II)
 - c. Morquio syndrome (MPS IV)
 - d. Sly syndrome (MPS VII)
 - e. Sanfillipo syndrome (MPS III)



Answers

b. Hunter syndrome (MPS II)

Explanation: All are autosomal recessive except hunter syndrome. Hunter syndrome is X linked recessive and thus is almost exclusively seen in males. This case is female and thus not expected to have an X linked disorder.



Case 4

A 3-year-old male with coarse facial features, progressive loss of motor skills, hepatosplenomegaly & chronic diarrhea is suspected of having **Hunter syndrome (MPS II)**. Which of the following monosaccharide residues would be expected to be found at the non reducing end of GAGs in this patient urine.

- a) N-acetyl glucosamine.
- b) N-acetyl galactosamine.
- c) Glucuronate.
- d) Iduronate.
- e) Iduronate 2- sulfate.



Answers:

e. Iduronate 2- sulfate

Explanation: Since the patient is suspected of having Hunter syndrome (MPS II) with deficiency of iduronate 2- sulfatase, iduronate 2- sulfate would be expected to be found at the non reducing end of GAGs in this patient urine.



Case 5

An 11-year-old boy was referred to the outpatient department for routine examination. Medical history reported that he had frequent respiratory infections and generalized weakness with easy fatigability. On examination, the patient had retarded growth with a short stature with mild mental retardation and hepatomegaly. Bony deformities, including kyphosis and rotated legs. The case was diagnosed as MPS II after the suitable lab investigations were done.

- a) What do you think the laboratory investigations were done to diagnose MPS II and their results?
- b) What is the treatment of this case?



Answers:

a) Lab. investigations for MPS II and their results:

1. Urinary GAG analyses:

- **Quantitative GAG assay:** revealed elevation of GAG compared to GAG levels in age-matched normal subjects.
- **Qualitative GAG assays:** revealed the type of GAG excreted (dermatan sulfate and heparan sulfate).

2. Enzyme activity assays: Iduronate-2-sulfatase enzyme activity in WBCs, fibroblasts or serum was decreased.

3. Molecular genetic testing: of mutation in the gene coding Iduronate-2-sulfatase enzyme was found.

b) Treatment of this **MPS II** case:

1) Enzyme replacement therapy.

2) Treatment of different clinical manifestations





Thank you